

**Ministry of Health of Ukraine  
National Pirogov Memorial Medical University, Vinnytsya**

«APPROVED»


by Methodical Council  
of dentistry disciplines

Protocol № 8

From "16" "03" 2025 y.

Head of the Methodical Council

Professor of HEI



Serhii SHUVALOV


“AGREED”

The head of the Examination

Commission No. 4

«27» "03" 2025 y.

Professor of HEI



Mariia SHINKARUK-DYKOVYTSKA

**EXAMINATION MATERIALS**

**Station No. 1 “BASIC CLINICAL EXAMINATION OF  
THE PATIENT IN THE THERAPEUTIC DENTISTRY  
CLINIC”**

**SPECIALTY**

**221 Dentistry**

**EDUCATIONAL PROGRAM**

**“Dentistry”**

**FACULTY**

**Faculty of Dentistry**

## **APPENDICES TO THE EXAMINATION MATERIALS**

1. Student Instructions at the Station (Appendix 1)
2. List of Practical Skills (Appendix 2)
3. Algorithms for Performing Practical Skills (Appendix 3)
4. Sample Task (Appendix 4)
5. Regulatory Documents (Appendix 5)

### **Appendix 1**

#### **STUDENT INSTRUCTIONS AT STATION №1: “BASIC CLINICAL EXAMINATION OF A PATIENT IN THE CLINIC OF THERAPEUTIC DENTISTRY”**

The higher education applicant (HEA) must greet the examiner and present their identification number assigned during registration for the OSCE. The station includes video recording of the HEA's performance. The HEA is provided with a clinical scenario involving communication with a patient, history taking including complaints and anamnesis, performance of necessary diagnostic procedures, determination of clinical management and treatment strategy, and disease prevention.

#### **Competencies to be assessed:**

**Communication skills:** ability to introduce oneself, explain the purpose of the interaction, obtain informed consent for interview and examination, listen attentively and communicate in a language understandable to the patient.

#### **Physical examination skills:**

1. Ability to examine a dental patient
2. Ability to justify and formulate a preliminary diagnosis
3. Ability to analyze examination results of a dental patient
4. Ability to diagnose common diseases of teeth, periodontium, and oral mucosa
5. Ability to determine the treatment tactics and strategy for patients

#### **Cognitive skills:**

- Clinical features and anatomical-histological structure of teeth, periodontium, oral mucosa, and oral organs
- Classifications of dental, periodontal, and oral mucosal diseases
- Main methods of dental patient examination
- Clinical signs of dental diseases
- Basic clinical and laboratory indicators of human body fluids and maxillofacial tissues
- Principles of differential diagnosis of dental diseases
- Principles and stages of dental treatment
- Types, levels, and measures of prevention of diseases of teeth, periodontium, and oral mucosa

**Ethical and legal competencies:** ability to explain the purpose and process of the procedure to the patient, as well as the importance of the obtained results

**List of Diseases:**

1. Non-carious lesions of hard dental tissues (hypersensitivity, enamel hypoplasia, enamel hyperplasia, fluorosis, dental hard tissue erosion, wedge-shaped defect, pathological tooth wear, dental hard tissue necrosis, discoloration, traumatic dental injuries)
2. Dental caries and its complications (pulpitis, periodontitis)
3. Periodontal diseases (papillitis, gingivitis, periodontitis, periodontosis, idiopathic periodontal conditions)
4. Diseases of the oral mucosa (traumatic lesions, autoinfectious diseases of the oral mucosa, secondary bacterial infections, oral mucosal diseases associated with autoimmune dermatoses, oral mucosal changes due to allergic reactions, oral mucosal changes due to heavy metal salt intoxication, symptomatic viral infections, oral mucosal manifestations of systemic internal diseases, diseases of the tongue and lips)
5. Precancerous conditions of the oral mucosa and vermilion border of the lips

**Material and Technical Support at the Station:** dental units, instruments for oral examination and periodontal screening, pulp tester, materials and medications used in the therapeutic dentistry clinic, caries detectors, cold spray, dental accessories, results of additional and laboratory diagnostic methods, checklists.

The clinical scenario involves interaction with a standardized patient and the completion of the tasks described in the instructions.

**When working with a standardized patient:**

1. The HEA must greet and introduce themselves.
2. Ask the patient how they prefer to be addressed.
3. After receiving the patient's name, inform them that you need to ask some questions and perform an examination. Ask for consent to proceed with the interview.
4. Ask the patient's age.
5. Ask for complaints (the patient will provide a main complaint that must be clarified according to the algorithm).
6. Clarify the complaint using the provided algorithm.
7. Before performing a physical examination, explain the purpose of the procedure (e.g., to determine the depth of a carious lesion).
8. Explain the process: for example, that you will perform probing of the carious cavity. Warn the patient about possible sensations during the procedure.
9. If necessary during the examination, ask the patient to inform you about any sensations (e.g., when using an electric pulp tester, instruct the patient to signal when they feel a sensation in the tooth).
10. Obtain informed consent from the patient for the objective examination or additional diagnostic methods.
11. Put on gloves and a mask.
12. Perform the objective examination or additional diagnostic procedures.
13. Before concluding the interaction with the patient, provide recommendations regarding treatment or disease prevention.

While performing the tasks specified in the clinical scenario, the student will be required to: evaluate the results of additional diagnostic methods, establish a clinical diagnosis, determine the treatment strategy, specify preventive measures.

After completing the task or when the allotted time has expired, the student must return the task to the instructor, wait for the signal indicating the end of the station, and then leave the station. After the time expires, the examiner will not accept any responses. The examiner acts solely as an observer and does not give instructions, comments, or ask questions.

After completing the first station, the HEA must proceed to the next station according to the route sheet.

**Duration and Time Allocation at the Station:**

<b>№</b>	<b>Actions</b>	<b>Time allocation (approximate)</b>
1.	Acquaintance with the task	1 min.
2.	Completing the task	7 min.
	<b>Total:</b>	8 min.

It is **STRICTLY FORBIDDEN** to communicate with the examiner, use educational or supplementary materials, use gadgets, transmit, copy, or disseminate any information related to the exam that is not publicly available. In case of violation of the above-mentioned rules by the higher education applicant, the examination will be terminated, and the result will be recorded as "fail" (due to violation of academic integrity regulations).

**MUST HAVE:** gloves, face mask

**Appendix 2**

**LIST OF PRACTICAL SKILLS AT THE STATION**

<b>Section</b>	<b>Title of the section</b>
<b>Section 1.</b>	General dentistry
1.1.	Communication with the patient
1.2.	Collection of complaints, anamnesis
1.3.	Objective examination of the patient
1.4.	Diagnosis of typical diseases
1.5.	Patient management tactics
1.6.	Treatment of typical diseases
1.7.	Prevention of typical diseases
1.8.	Ethical aspects
<b>Section 2.</b>	<b>Therapeutic dentistry</b>
2.1.	Clinical examination of teeth, dentition, periodontal tissues and oral mucosa;
2.2	Periodontal screening (gum relief, periodontal pocket depth, bleeding, tooth mobility, gingival and periodontal indices)
2.3	Additional research methods (cold test, electroodonto-diagnostics, diagnostic use of dyes, interpretation of the results of radiological diagnostics of the oral cavity).
2.4	Conducting professional oral hygiene for various dental diseases, taking into account the general somatic status of the patient
2.5	Selection of oral hygiene items and means, hygienic education of the patient, drawing up an individual prevention plan
2.6	Coating teeth with therapeutic and preventive varnishes, gels
2.7	Local anesthesia in the treatment of dental diseases by various methods (application, infiltration, nerve block)

**LIST OF TASKS AND PRACTICAL SKILLS FOR COMPILING THE OSP(C)E  
FOR STATION No. 1**

<b>№</b>	<b>Diagnosis</b>	<b>Complaints, anamnesis (1.5 points)</b>	<b>Diagnostics (1.5 points)</b>	<b>Tactics and treatment (1.5 points)</b>	<b>Prevention (1.5 points)</b>
1	Caries – incipient, superficial, middle, deep (acute and chronic)	Ask about pain, presence of a carious cavity / aesthetic defect. Clarify the complaints in detail. Collect the history of the disease. Inquire about oral hygiene habits. Ask about the presence of systemic conditions.	Basic diagnostic methods (inspection, probing, percussion, palpation – assessment of cavity depth and tooth tissue consistency). Interpretation of additional diagnostic methods – EPT (electric pulp testing), cold test, dye test.	Depending on the stage of the process: Remineralizing therapy. Infiltration treatment techniques. Cavity preparation considering the topography of the defect and selection of filling material, restoration of the anatomical tooth shape.	Provide recommendations to the patient regarding personal and professional hygiene. Diet therapy. Schedule a repeat preventive examination.
2	Non-carious lesions of hard dental tissues – erosion, wedge-shaped defect, hypoplasia	Ask about dentin hypersensitivity and aesthetic defect. Clarify the complaints in detail. Collect the history of the disease. Ask about the presence of comorbid conditions.	Basic diagnostic methods (inspection, probing, percussion, palpation – assessment of defect depth and tooth tissue consistency). Interpretation of additional diagnostic methods – EPT, cold test, dye test.	Referral to appropriate related medical specialists. Depending on the stage of the process: Remineralizing therapy. Infiltration techniques. Minimally invasive defect preparation, restoration with a filling material.	Treatment of concomitant general somatic pathology. Provide recommendations to the patient on personal and professional hygiene. Diet therapy. Schedule a repeat preventive examination.
3	Pulpitis – acute (pulp hyperemia, circumscription, diffuse, purulent, traumatic) and chronic (fibrous, hypertrophic, gangrenous, concrementous)	Determine the nature of the pain, duration of pain-free intervals, and factors that relieve the pain. Collect the history of the disease. Ask about the presence of	Basic diagnostic methods (inspection, probing, percussion, palpation). Interpretation of additional diagnostic methods – EPT, cold test, radiographic examination results.	Depending on the stage of the process and case conditions: Biological treatment method. Vital pulpotomy. Vital and devital pulpectomy.	Provide recommendations to the patient depending on the chosen method (for example, if a painful reaction occurs after treatment).

	e)	comorbid conditions.			Provide recommendations to the patient regarding personal hygiene and oral hygiene. Schedule a repeat preventive examination.
4	Apical periodontitis – acute (serous, purulent) and chronic (fibrous, granulating, granulomatous)	Determine the nature of the pain, identify triggering and relieving factors. Collect the history of the disease. Ask about the presence of comorbid conditions.	Basic diagnostic methods (inspection, probing, percussion, palpation). Interpretation of additional diagnostic methods – EPT, cold test, radiographic examination results.	Depending on the diagnosis and case conditions: Endodontic treatment in 1-2-3 visits. If it is not possible to complete treatment in one visit – temporary root canal filling. Subsequent restoration of the anatomical tooth shape.	Provide recommendations to the patient in the immediate post-treatment period (e.g., if a painful reaction occurs after treatment). Provide recommendations to the patient regarding personal hygiene and oral hygiene. Schedule a repeat preventive examination.
5	Gingivitis – catarrhal, hypertrophic, necrotizing-ulcerative	Ask about gingival bleeding and gum pain. Ask about oral hygiene habits. Collect the history of the disease. Ask about the presence of systemic conditions.	Periodontal screening (inspection, evaluation of dentoepithelial attachment, degree of bleeding), determination of Schiller-Pisarev test, gingival indices, Mühlemann bleeding index.	Professional oral hygiene. Elimination of traumatic factors. Local drug therapy depending on the diagnosis and activity of the process (local anesthetics, anti-inflammatory agents, antiseptics, antibacterial and keratoplastic agents).	Treatment of concomitant pathology. Provide recommendations to the patient on personal and professional hygiene. Diet therapy. Schedule a repeat preventive examination.

6	Periodontitis – localized, generalized (initial, stage I, stage II, stage III)	Ask about gingival bleeding and gum pain. Ask about oral hygiene habits. Collect the history of the disease. Ask about the presence of systemic conditions	Periodontal screening (inspection, determination of periodontal pocket depth, degree of bleeding, evaluation of supra- and subgingival calculus), assessment of periodontal indices, Mühlemann bleeding index, interpretation of radiographic examination results.	Follow the stages of the treatment plan: Professional hygiene. Medication therapy (choose based on the clinical situation and activity of the process). Elimination of the periodontal pocket (select method depending on the clinical situation). Stabilization of the dental arch (selective grinding, splinting, prosthetics – depending on the clinical situation). Supportive therapy.	Treatment of concomitant pathology. Provide recommendations to the patient on personal and professional hygiene. Diet therapy. Schedule a repeat preventive examination.
7	Auto-infectious diseases of the oral mucosa – viral, bacterial, fungal	Identify main complaints and clarify them in detail. Identify contributing factors for disease development. Collect the history of the disease. Ask about the presence of systemic conditions.	Perform inspection of the oral mucosa and vermillion border of the lips. Identify primary and secondary lesion elements (based on clinical photo). Perform palpation of lymph nodes and oral mucosa. Evaluate the results of additional diagnostic methods.	Referral to related specialists if necessary. Etiopathogenetic and symptomatic treatment, general and local – depending on the clinical situation.	Treatment of concomitant pathology. Sanitation of foci of chronic infection. Provide recommendations to the patient on individual oral hygiene. Diet therapy. Schedule a repeat preventive examination.

## ALGORITHMS FOR PERFORMING PRACTICAL SKILLS

### 1. Collection of complaints (with details) and medical history

#### Tooth pain

##### 1. If the pain is triggered by stimuli or occurs spontaneously:

*If the pain is triggered by stimuli:*

- What stimuli cause the pain?  
*(If necessary, clarify: sweet, cold, hot, biting, food getting into a carious cavity)*
- What is the intensity of the pain when exposed to stimuli?  
*(If necessary, clarify: severe/intense pain or mild/dull/unpleasant sensations)*
- How long does the pain last after the stimulus is removed?  
*(If necessary, clarify: disappears immediately, lasts for several minutes, persists for a long time – more than 5-10 minutes)*
- What is the nature of the pain when exposed to stimuli?  
*(If necessary, clarify: sharp, throbbing, dull, pulling, unpleasant sensations)*
- Can you point out which specific tooth hurts?
- If the patient reports severe, intense pain – did you try to relieve it yourself?  
*(If necessary, clarify: did you take analgesics/painkillers, rinse the tooth, etc.)*

*If the pain is spontaneous:*

- Is the pain constant or episodic?
- How long does a pain episode last?  
*(If necessary, clarify: more than 1-2 minutes, more than 5-10 minutes, more than 30 minutes, almost constant)*
- How long are the pain-free intervals?  
*(If necessary, clarify: several hours, up to one hour, almost none)*
- Are there any factors that worsen the pain?  
*(If necessary, clarify: worsens from cold, hot, or biting)*
- What is the nature of the pain?  
*(If necessary, clarify: sharp, throbbing, shooting, dull, pulling)*
- Can you point out which specific tooth hurts?
- Are there any factors that relieve the pain?  
*(If necessary, clarify: relieved by cold, warm, or tooth clenching)*
- If the patient reports severe, intense pain – did you try to relieve it yourself?  
*(If necessary, clarify: did you take analgesics/painkillers, rinse the tooth, etc.)*

*Medical history (anamnesis):*

- When did this pain first occur?
- How has the character of the pain changed since it started?
- Have you experienced similar pain before?
- Did you try to manage the pain yourself?
- Has this tooth been treated before? Can you recall what kind of treatment was performed?

#### **Presence of a carious cavity / aesthetic defect**

- How long ago did you notice the defect?
- Do you experience any pain in the tooth?
- Have you previously experienced any pain in this tooth?
- Has this tooth been treated before? Can you recall what kind of treatment was performed?

**Tooth hypersensitivity**

- What kind of stimuli cause the pain? (Three degrees of hypersensitivity are distinguished: Grade I – response mainly to thermal stimuli, Grade II – pain also occurs from chemical stimuli, Grade III – pain from all types of stimuli: thermal, chemical, and tactile)
- Is the pain localized or generalized?
- How long have you been experiencing increased sensitivity?
- What triggered the onset of this sensitivity?  
(Possible causes: hard tissue defects, pathological tooth wear, tooth preparation for prosthetic restoration, exposure of tooth necks or roots, systemic diseases)
- Have you received any treatment before? What was the outcome?

**Gum bleeding**

- What kind of stimuli cause the bleeding? (Three degrees of bleeding are distinguished: Grade I – bleeding occurs during tooth brushing, Grade II – while eating, Grade III – spontaneous bleeding)
- How long have you been experiencing gum bleeding?
- Do you feel any pain in your gums?
- How do you maintain oral hygiene? What type of toothbrush do you use? What kinds of toothpaste?
- When was your last professional dental cleaning?
- Do you have any harmful habits? (e.g., smoking, alcohol use, drug use)
- Do you have any internal organ diseases? If yes, which ones? When did you last see the relevant specialists?
- Are you currently taking any medications?

**Pain in the gums / oral mucosa**

- What stimuli cause the pain?
- What is the nature of the pain?  
(If needed, clarify: sharp, throbbing, dull, pulling, unpleasant sensations)
- What is the intensity of the pain?  
(If needed, clarify: strong/intense pain or mild/dull/unpleasant sensations)
- Is the pain localized or does it radiate to other areas?
- Is the pain accompanied by fever or general malaise?
- How long have you been experiencing this pain?
- Can you recall what preceded the onset of pain?
- Have you experienced similar pain before?
- Did you try anything to relieve the pain?  
(e.g., medication, mouth rinses, etc.)

**During anamnesis taking, clarify the following information for all patients:**

- Age, occupation, presence or absence of occupational hazards, dietary habits, past illnesses, stress conditions, environmental, social, and living conditions.
- How do you maintain oral hygiene? What type of toothbrush do you use? What kinds of toothpaste?
- When was your last professional dental cleaning?
- Do you have any harmful habits? (e.g., smoking, alcohol use, use of psychoactive substances, etc.)
- Do you have any internal organ diseases? If so, which ones? When did you last consult the relevant specialists?
- Are you currently taking any medications?

- Do you have a tendency toward allergic reactions?

## **2. Extraoral examination of the patient's face and palpation of the lymph nodes**

- Position the patient ergonomically for the examination.
- Briefly explain the purpose of the procedure to the patient. Inform them that palpation of the skin or lymph nodes may cause pain or discomfort.
- Put on gloves and a mask.
- Perform an extraoral examination of the patient's face: assess facial proportions and symmetry; presence of swelling or masses; skin color; presence of lesions; prominence of the nasolabial and labiomental folds; and the appearance of the vermilion border of the lips.
- Perform palpation of the lymph nodes: assess consistency, mobility, tenderness, size, and relation to surrounding tissues.

## **3. Clinical Examination of a Patient with Odontopathology**

- Briefly explain the procedure to the patient. Inform the patient that discomfort or pain may occur during probing, percussion, or palpation.
- Examine the affected tooth and assess the presence of a carious cavity or restoration.
- Inspect the teeth using a dental mirror and probe. The examination begins with the last tooth on the upper right side, proceeds through all upper teeth, then moves down to the last tooth on the lower left side, and concludes with the last tooth on the lower right side. During the examination, assess: number of teeth; position within the dental arch; mobility; color, shape, size; presence of lesions.
- Evaluate the condition of restorations:
  - Marginal adaptation (by probing): a) no visible gap; b) visible gap; c) visible dentin and base material; d) defective filling, chipping, mobility, or loss of filling.
  - Condition of contact point
  - Degree of wear
  - Presence of secondary caries
  - Color stability
  - Anatomical shape of the filling
  - Color change between the filling and the tooth wall
  - Color matching of the restoration to the tooth structure (color, translucency)
- Perform probing of the affected tooth, assessing the depth of the carious cavity, consistency of the hard tissues, tenderness, and whether there is communication between the cavity and the pulp chamber.
- Perform vertical, horizontal, and comparative percussion.
- Perform palpation of the oral mucosa in the projection area of the tooth root apex.

## **4. Periodontal Screening**

- Position the patient ergonomically for the examination.
- Briefly explain the procedure to the patient. Inform them that discomfort or pain may occur during the assessment.
- Put on gloves and a mask.
- Examine the gingiva: assess color, surface characteristics, texture, presence of hypertrophy or recession, and presence of periodontal pockets.
- Using a periodontal probe and explorer, assess the integrity of the dentoepithelial attachment.
- If a periodontal pocket is present, determine its depth:
  - Isolate the tooth from saliva using cotton rolls and dry it.

- Insert the periodontal probe into the pocket along the vertical axis of the tooth until a slight resistance is felt. Make movements only perpendicular to the gingival margin, keeping the working part of the probe pressed against the tooth surface.
- Measure the depth of the periodontal pocket at four sites around the tooth: mesial, buccal (vestibular), distal, and lingual (oral). From the buccal and oral sides, take at least three measurements each: one at the center of the pocket and two at its periphery.
- When analyzing the results, record the maximum depth of the pocket at its deepest point.
- In the case of gingival hypertrophy, measure pocket depth from the level of the cemento-enamel junction.

## **5. Clinical Examination of a Patient with Oral Mucosal Disease**

- Place the patient in an ergonomic position for examination.
- Briefly explain the procedure to the patient. Warn that unpleasant or painful sensations may occur during the examination.
- Put on gloves and a face mask.
- Perform an examination of the oral mucosa, evaluating the color, surface characteristics, and presence of pathological elements. The examination should be carried out in the following sequence:
  - Oral vestibule (depth, color);
  - Labial frenula (attachment site, density);
  - Lingual frenulum (attachment site, density);
  - Oral mucosa and tongue (color, glossiness, surface texture, turgor, vascular pattern, presence of lesions, plaque, tooth imprints).
- Perform palpation of the oral mucosa, evaluating tissue consistency, tenderness, and the presence of exudate from pathological elements.
- Identify primary lesions on the oral mucosa. These include macule, papule, nodule, tubercle, pustule, cyst, vesicle, blister, and abscess.
- Identify secondary lesions on the oral mucosa. These include erosion, aphtha, ulcer, fissure, scar, plaque, scale, crust, excoriation, and lichenification.
- When evaluating secondary lesions, pay attention to the following parameters: topography, size, shape, color, stage of development, nature of discharge, base and depth of the defect, tissue consistency, tenderness, appearance of surrounding tissues, and the presence of other lesion types.

## **6. Determining the Indicators of Electroodontodiagnostics**

- Place the patient in an ergonomic position for the procedure.
- Briefly explain the purpose of the procedure – to assess pulp sensitivity to electric current to evaluate the tooth's vitality.
- Put on gloves and a face mask.
- Carefully isolate the tooth from saliva; dry the tooth surface thoroughly to avoid electrical stimulation of the gingiva, which could result in a false response. Pay special attention to drying adjacent areas to prevent current from reaching a nearby tooth, which may also lead to false results.
- Attach the stainless-steel hook (lip clip) to one corner of the patient's mouth.
- Apply a drop of conductive paste or toothpaste between the test electrode and the selected tooth.
- Instruct the patient to signal as soon as they feel the first sensation in the tooth (twitching or mild pain).

- Set the current regulator to 0, fix the test electrode to the tooth surface, switch on the device, and gradually increase the current until the patient reports a response.
- Record the electroodontodiagnostic reading and evaluate the result:
  - Normal pulp sensitivity: 2–6  $\mu\text{A}$
  - Middle caries: 6–8  $\mu\text{A}$
  - Chronic deep caries: 8–12  $\mu\text{A}$
  - Acute deep caries: 10–18  $\mu\text{A}$
  - Pulp hyperemia: 15–20  $\mu\text{A}$
  - Acute localized pulpitis: 18–25  $\mu\text{A}$
  - Acute diffuse pulpitis: 25–35  $\mu\text{A}$
  - Acute purulent pulpitis: 35–50  $\mu\text{A}$
  - Chronic fibrous pulpitis: 35–55  $\mu\text{A}$
  - Chronic gangrenous pulpitis: 60–80  $\mu\text{A}$
  - Apical periodontitis: over 100  $\mu\text{A}$

## **7. Cold Test**

- Provide the patient with an ergonomic position for examination.
- Briefly explain the essence of the procedure to the patient – determining the tooth's response to a refrigerant spray to assess its vitality. Inform the patient that the procedure may cause pain or discomfort.
- Wear gloves and a mask.
- Isolate the dental arch from saliva using cotton rolls; dry the surface of both the intact and suspected teeth. Apply a cotton pellet soaked in refrigerant spray precisely to the enamel.
- First test the response of the intact tooth, then assess the sensitivity of the suspected tooth.
- Evaluate the speed of the pain response and its duration:
  - Pain lasting 3–5 seconds – healthy tooth.
  - Cold test relieves the pain – sign of purulent pulpitis.
  - Pain lasting up to 15 seconds – reversible pulpitis.
  - Pain lasting more than 30 seconds – irreversible pulpitis.
  - No response to cold – periodontitis, non-vital tooth.

## **8. Dye Test**

- Provide the patient with an ergonomic position for examination.
- Briefly explain the essence of the procedure – to detect signs of hard dental tissue demineralization.
- Wear gloves and a mask.
- Apply a dye solution to the dried tooth surface, leave for 1–2 minutes, and rinse off. More intense staining of the defect indicates demineralization processes in hard tissues.

## **9. Schiller–Pisarev Test**

- Provide the patient with an ergonomic position for examination.
- Briefly explain the essence of the procedure – to identify signs of gingival or oral mucosa inflammation.
- Ask the patient if they have any known allergy to iodine.
- Wear gloves and a mask.
- Using a cotton swab soaked in the Schiller–Pisarev solution, coat the gums.
- Assess the test result based on staining intensity:

- Negative – light yellow coloration;
- Positive – dark brown coloration.

#### **10. Loe-Silness Gingival Index**

- Provide the patient with an ergonomic position for examination.
- Briefly explain the essence of the procedure – to assess the severity of gingivitis.
- Wear gloves and a mask.
- Assess the condition of the gums on the vestibular, lingual, mesial, and distal surfaces of the tooth. Score each of the 4 sides as follows:
  - 0 – normal gingiva;
  - 1 – mild inflammation, slight color change, mild edema, no bleeding on probing;
  - 2 – moderate inflammation, red and swollen gingiva, bleeding on probing;
  - 3 – severe inflammation, marked redness and edema, ulceration, spontaneous bleeding tendency.
- Calculate the index using the formula:  $GI = \text{sum of scores} / 4$
- Interpret the result as follows:
  - 0.1–1 – mild gingivitis;
  - 1.1–2 – moderate gingivitis;
  - 2.1–3 – severe gingivitis.

#### **11. PMA Index – Qualitative and Quantitative Assessment**

- Provide the patient with an ergonomic position for examination.
- Briefly explain the essence of the procedure to the patient – to determine the severity of gingivitis.
- Wear gloves and a mask.

##### **Qualitative PMA Index Assessment:**

- Using a dental mirror and probe, visually assess the presence of gingival inflammation near each individual tooth, scoring as follows:
  - 1 – inflammation of the papilla (P);
  - 2 – inflammation of the marginal gingiva (M);
  - 3 – inflammation of the attached (alveolar) gingiva (A).
- The PMA index is calculated by summing the scores for the marginal periodontium of all teeth (always expressed as a whole number).

##### **Quantitative PMA Index Assessment:**

- Calculate the PMA index as a percentage using the S. Parma modification (1960) with the following formula:

$\text{PMA Index (\%)} = \text{Number of affected gingival units} \times 100 / 3 \times \text{Total number of teeth examined}$

- Interpret the PMA (Parma) index as follows:
  - up to 25% – mild gingivitis;
  - 25–50% – moderate gingivitis;
  - more than 50% – severe gingivitis.

#### **12. Papillary Bleeding Index (PBI) by Saxer and Muhlemann**

- Provide the patient with an ergonomic position for examination.
- Briefly explain the essence of the procedure – to assess the degree of gingival bleeding. Inform the patient that discomfort may occur during the procedure.
- Wear gloves and a mask.
- Isolate the dental arch from saliva using cotton rolls and dry the gingival surface.

- Using a periodontal probe, gently probe the gingival papilla to assess bleeding after manipulation. Perform probing on the lingual surfaces of the first and third quadrants, and on the buccal (vestibular) surfaces of the second and fourth quadrants. Insert the probe at a 45° angle into the gingival sulcus to a depth of up to 5 mm and move it gently along the mesial and distal parts.

**Assess the results as follows:**

- Grade 0: no bleeding;
- Grade 1: isolated pinpoint bleeding;
- Grade 2: multiple pinpoint bleeding spots or linear bleeding;
- Grade 3: interdental papilla filled with blood;
- Grade 4: intense bleeding following probing; blood flows along the tooth or gums.
- Calculate the index value separately for each quadrant, then determine the average value for the entire dentition.

**13. Periodontal Index by Russell**

- Provide the patient with an ergonomic position for examination.
- Briefly explain the purpose of the procedure – to determine the severity of periodontitis. Inform the patient that some discomfort may occur during the examination.
- Wear gloves and a mask.
- Isolate the teeth from saliva using cotton rolls and dry them.
- Using a dental mirror and probe, visually assess the condition of the periodontal tissues of each tooth (excluding third molars), scoring each according to the following criteria:
  - 0 – no apparent inflammation, normal structure and function of the periodontium;
  - 1 – mild gingival inflammation not involving the entire tooth circumference;
  - 2 – gingivitis (inflammation around the tooth without disruption of epithelial attachment, no periodontal pocket);
  - 4 – early stage of resorption of the crests of the interdental septa detectable radiographically;
  - 6 – gingival inflammation with the formation of a periodontal pocket, epithelial attachment is disrupted, but no functional loss of the periodontium, the tooth is not mobile;
  - 8 – advanced destruction of periodontal tissues with loss of chewing function, tooth is mobile and may be displaced.
- In doubtful cases, assign the lower score.
- Calculate the index using the formula:

PI = Total score of all teeth assessed ÷ Number of teeth examined Interpret the PI as follows:

- 0–0.1 – clinically healthy gingiva;
- 0.1–1.0 – mild gingivitis;
- 0.5–1.9 – early and Stage I generalized periodontitis;
- 1.5–4.0 – Stage II generalized periodontitis;
- 4.0–8.0 – Stage III generalized periodontitis.

**14. Evaluation of Radiological Examination Results**

1. Assess the quality of the radiograph  
Examine the patient's periapical radiograph or orthopantomogram. Determine the image quality and its suitability for diagnostic use: the radiograph should be contrasty, clear, structured, and free from projection distortions.
2. Assess the dental arches and surrounding bony anatomical structures

- Evaluate the integrity of the dental arches, the position of individual teeth, and the presence of prosthetic or orthodontic appliances.
- Assess the surrounding anatomical structures. On maxillary radiographs, observe the floor of the nasal cavity, nasal septum, inferior nasal meatus, anterior nasal spine, intermaxillary suture, incisive foramen, floor of the maxillary sinus, and zygomatic bone. On mandibular radiographs, the anterior region reveals the mental protuberance, and the posterior region shows three structures: the mental foramen, mandibular canal, and external oblique ridge.
- Evaluate the condition of the alveolar bone:
  - In *chronic periodontitis*, identify destruction of the cortical plate in the area of the interdental septa apices, areas of osteoporosis in the alveolar bone, and a coarse trabecular pattern. Note uneven resorption of the alveolar process (vertical and horizontal types), the presence of bony pockets, and widening of the periodontal ligament space.
  - In *periodontosis*, detect discontinuity of the cortical plate of the alveolar process, areas of osteosclerosis in the cancellous bone, uniform decrease in the height of the interdental septa (horizontal type of bone resorption), a fine trabecular pattern, hypercementosis at the root apices, pulp chamber sclerosis, and denticle formation.
- Determine the amount of resorption of the interdental septa to assess the severity of periodontal disease:
  - Initial stage: osteoporosis of the apical part of the interdental septa, destruction of the compact bone plate, minor resorption.
  - *Stage I*: resorption of up to 1/3 of the root length.
  - *Stage II*: resorption from 1/3 to 2/3 of the root length.
  - *Stage III*: resorption exceeding 2/3 of the root length.
- 3. Assess periapical changes for each tooth
  - In *chronic fibrous periodontitis*, there is widening of the periodontal ligament space at the root apex and its deformation, while the compact bone plate of the alveolar bone retains clear contours.
  - In *chronic granulating periodontitis*, there is rarefaction of the periapical tissues without clear borders in a "flame-shaped" pattern, along with resorption of the root cementum and dentin.
  - In *chronic granulomatous periodontitis*, a round bone destruction focus up to 0.5 cm in diameter is seen, surrounded peripherally by condensed cancellous bone.

## Appendix 4

### SAMPLE TASKS

#### Station №1: Basic Clinical Examination of a Patient in the Therapeutic Dentistry Clinic CLINICAL SCENARIO FOR THE STUDENT №1

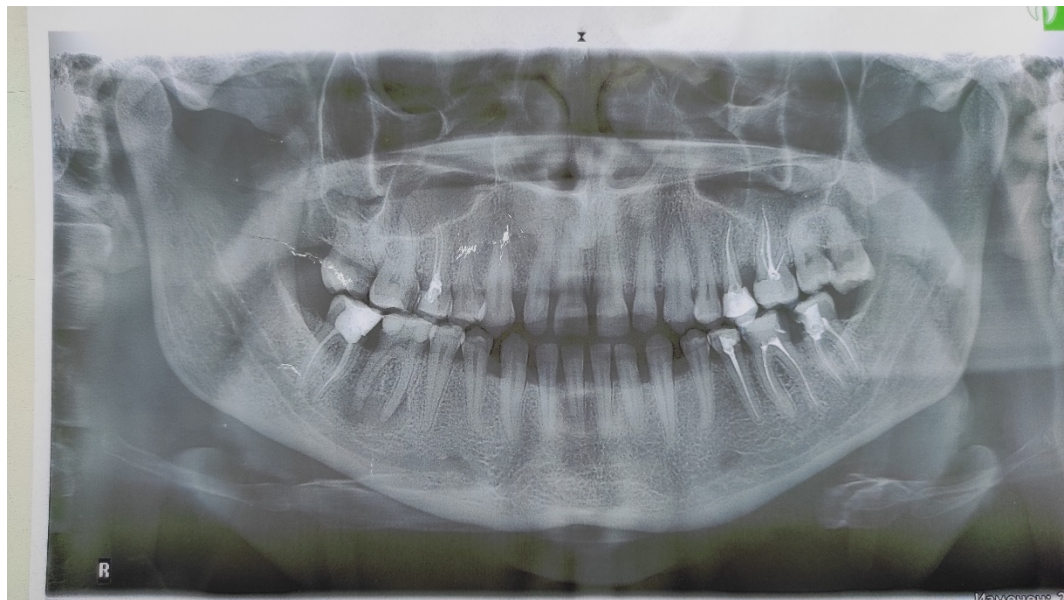
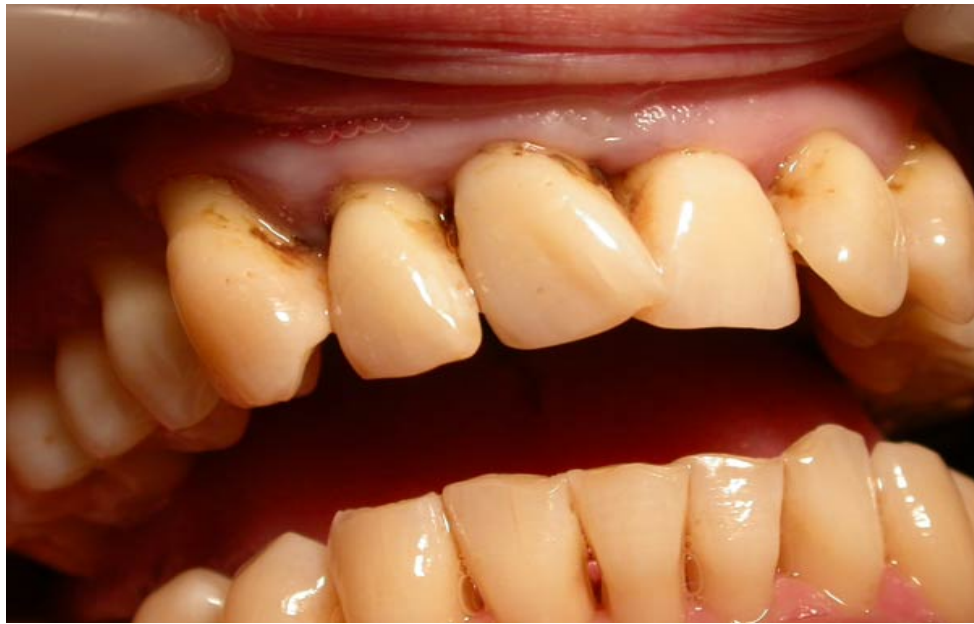A 53-year-old patient presents with complaints of bleeding gums and tooth mobility.

Objective findings: the gingiva is congestively hyperemic; periodontal pockets of 3-4 mm depth are detected; Grade I tooth mobility is observed; moderate amounts of supra- and subgingival calculus are present. A clinical photograph is provided.

Materials available: periodontal screening instrument set, the patient's orthopantomogram.

#### Tasks related to clinical scenario №1:

1. Clarify the patient's complaints in more detail and take a medical history.
2. Perform periodontal screening.
3. Evaluate the results of the radiological examination.
4. Establish a diagnosis.
5. Determine the treatment plan for the patient.
6. Specify preventive measures and provide patient recommendations.



## CLINICAL SCENARIO No 1 STANDARDIZED PATIENT SCRIPT

You are simulating a 53-year-old patient with chronic generalized periodontitis, Stage II.  
Only answer the questions asked by the student. For any off-script questions, respond with: “I don’t know” or “I don’t remember.”

Questions Asked by the Student	Tutor’s Responses
What are your complaints?	Bleeding gums and tooth mobility.
When does the bleeding occur?	During tooth brushing.
Does bleeding happen while eating?	Sometimes while eating hard food.
Do you experience spontaneous bleeding?	No.
Do you feel any pain in your gums?	Sometimes there is pain, but at the moment I don’t feel any.

How long have you been experiencing bleeding?	For the past 5 years.
How long ago did you notice tooth mobility?	Over the past year.
Have you received any treatment before?	Yes, I receive periodic treatment from a periodontist.
When was your last visit to a periodontist?	A year ago.
Do you treat yourself at home?	Sometimes I rinse with herbal decoctions.
How do you maintain your oral hygiene?	I brush my teeth twice a day.
Do you have any internal (systemic) diseases?	Yes, I have a peptic ulcer and chronic colitis.
Are there any current exacerbations of your internal conditions?	No, there are no current exacerbations.

No pain complaints occur during clinical examination.

### CHECKLIST

#### Skills assessment at the OSP(C)E station

#### Station No. 1 “Basic clinical examination of a patient in a therapeutic dentistry clinic”

##### Clinical situation No. 1

№	Practical Skills	Number of points per skill	Number of points for the applicant
<b>1</b>	<b>History Taking and Complaint Assessment</b>	<b>1.5</b>	
1.1	Collected and clarified complaints of gum bleeding.	0.3	
1.2	Inquired about gum pain.	0.3	
1.3	Inquired about tooth mobility.	0.3	
1.4	Collected medical history of the disease.	0.3	
1.5	Identified comorbid gastrointestinal condition.	0.3	
<b>2</b>	<b>Diagnostics</b>	<b>1.5</b>	
2.1	Detected periodontal pockets 3–4 mm deep.	0.3	
2.2	Identified grade II gingival bleeding.	0.3	
2.3	Identified grade I tooth mobility.	0.3	
2.4	Detected resorption of interalveolar septa up to ½ root length on radiograph.	0.3	
2.5	Formulated diagnosis: generalized periodontitis, grade II, chronic course.	0.3	
<b>3</b>	<b>Treatment and Management</b>	<b>1.5</b>	
3.1	Performed professional oral hygiene.	0.3	
3.2	Applied local anti-inflammatory treatment.	0.3	
3.3	Applied local antiseptic treatment.	0.3	
3.4	Performed periodontal pocket curettage.	0.3	

3.5	Applied splinting and stabilization of the dental arch.	0.3	
<b>4</b>	<b>Prevention</b>	<b>1.5</b>	
4.1	Provided patient with toothbrush recommendations.	0.3	
4.2	Provided recommendations on toothpastes and mouthwashes.	0.3	
4.3	Advised on the use of additional oral hygiene aids (dental floss, interdental brushes, oral irrigator).	0.3	
4.4	Scheduled routine follow-up visit with professional cleaning in 6 months.	0.3	
4.5	Recommended referral to a gastroenterologist for systemic condition management.	0.3	
	<b>Maximum points per station</b>	<b>6.0</b>	<b>####</b>
	<b>The amount of points scored by the applicant</b>	<b>####</b>	

## Appendix 5

### REGULATORY DOCUMENTS ON THE BASIS OF WHICH CLINICAL CASES HAVE BEEN CREATED (for the last 5 years)

1. Standard of medical care “Anesthesia support in outpatient dentistry” (Order of the Ministry of Health of Ukraine dated March 27, 2025 No. 555)
2. Evidence-based clinical guideline “Anesthesia support in outpatient dentistry” (Order of the Ministry of Health of Ukraine dated March 27, 2025 No. 555)
3. Standard of medical care “Dental caries” (Order of the Ministry of Health of Ukraine dated May 23, 2024 No. 869)
4. Evidence-based clinical guideline “Dental caries” (Order of the Ministry of Health of Ukraine dated May 23, 2024 No. 869)
5. Standards of medical care “Dentoalveolar trauma” (Order of the Ministry of Health of Ukraine dated February 17, 2023 No. 314)
6. Standard of medical care “Rational use of antibacterial and antifungal drugs for therapeutic and prophylactic purposes” (Order of the Ministry of Health of Ukraine dated 08/23/2023 No. 1513)
7. Operative Dentistry. Endodontics: in 2 volumes. Volume 1: textbook edited by Prof. A.V. Borysenko / M.Yu. Antonenko, L.F. Sidelnikova, O.F. Nesyn et al. – 2nd edition, 2020, 384 p. ISBN: 978-617-505-788-9.
8. Stomatology: textbook: in 2 books. Book 1 / M.M. Rozhko, Z.B. Popovych, V.D. Kuroiedova et.al.; edited by M.M. Rozhko. – Kyiv: AUS Medicine Publishing, 2020. – 792 p.
9. Stomatology: textbook: in 2 books. Book 2 / M.M. Rozhko, Z.B. Popovych, V.D. Kuroiedova et.al.; edited by M.M. Rozhko. – Kyiv: AUS Medicine Publishing, 2020. – 792 p.
10. Preclinical Manual of Conservative Dentistry and Endodontics / 4th Edition, ed. by V. Gopikrishna / Elsevier - Saunders, Mosby, Churchill, 2023.
11. Textbook of Preclinical Conservative Dentistry: textbook edited by Nisha Garg, Amit Garg – 3<sup>rd</sup> edition. – Jaypee Brothers Medical Publisher, 2022. – 190 p.

12. Srikumar G.P.V., Wasule A. Non-Carious Lesions and Its Management: A Rollercoaster Ride, LAP Lambert Academic Publishing, 2023. – 304 p.
13. Newman M. Newman and Carranza's. Clinical Periodontology and Implantology. 1900 ed. [S.l.]: [s.n.], 2023.
14. Yussif N., Akarslan Z. Periodontal Disease: Diagnostic and Adjunctive Non-surgical Considerations. – BoD–Books on Demand, 2020.
15. Gehrig, Jill S, and Daniel E Shin. Foundations of Periodontics for the Dental Hygienist. Sixth edition. Burlington, MA: Jones & Bartlett Learning, 2023.
16. Enno Schmidt. Diseases of the Oral Mucosa. – 2021. – 550 p. DOI: <https://doi.org/10.1007/978-3-030-82804-2>